

# Treatment of Atrophic Facial Acne Scars With the 1064-nm Q-Switched Nd:YAG Laser

## Six-Month Follow-up Study

Paul M. Friedman, MD; Ming H. Jih, MD, PhD; Greg R. Skover, PhD; Greg S. Payonk, PhD; Arash Kimyai-Asadi, MD; Roy G. Geronemus, MD

**Objectives:** To quantitatively assess improvement in acne scarring after a series of nonablative laser treatments and to determine efficacy at 1-, 3-, and 6-month follow-up after treatment.

**Design:** Before-after trial of consecutively selected patients.

**Setting:** Private practice at the Laser and Skin Surgery Center of New York, New York.

**Patients:** Eleven patients with mild to moderate atrophic acne scarring were treated.

**Interventions:** A 3-dimensional optical profiling imaging system was used to assess skin topography before, during, and after treatment. Patients were treated with a 1064-nm Q-switched Nd:YAG laser and reassessed after 3 treatment sessions and at 1, 3, and 6 months after the fifth treatment session.

**Main Outcome Measures:** The skin roughness analy-

sis was quantified at baseline and at each follow-up interval. Pain, erythema, and petechiae formation were assessed on 3-point scales.

**Results:** At midtreatment (1 month after the third treatment session), an 8.9% improvement in roughness analysis was seen. This improvement increased to 23.3%, 31.6%, and 39.2% at 1, 3, and 6 months after the fifth treatment, respectively. Patients reported mild to moderate pain with treatment. The only adverse effects noted were transient erythema and mild pinpoint petechiae.

**Conclusions:** Treatment with the nonablative 1064-nm Q-switched Nd:YAG laser results in significant quantitative improvements in skin topography in patients with mild to moderate atrophic acne scars. Continued incremental improvements were noted at 1-, 3-, and 6-month follow-up, indicating ongoing dermal collagen remodeling after the treatment.

*Arch Dermatol.* 2004;140:1337-1341

**Author Affiliations:** DermSurgery Associates (Drs Friedman, Jih, and Kimyai-Asadi), and Department of Dermatology, University of Texas Medical School (Dr Friedman), Houston; Innovation Incubator, Johnson & Johnson Consumer Companies, Inc, Skillman, NJ (Drs Skover and Payonk); and Laser and Skin Surgery Center of New York, New York (Dr Geronemus).  
**Financial Disclosure:** None.

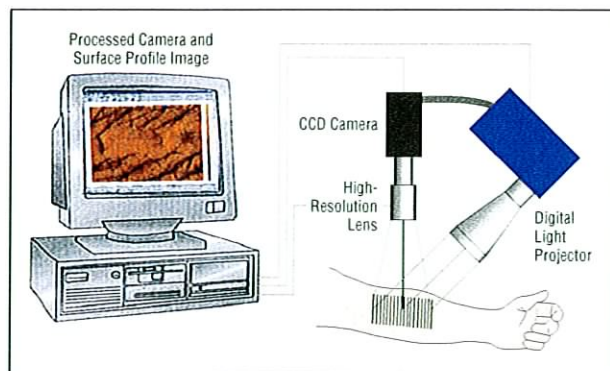
**A**TROPHIC ACNE SCARS ARE often permanent sequelae of inflammatory acne. Because of the significant cosmetic burden of these scars, patients frequently seek medical treatment. Acne scars can be revised through a variety of techniques, including dermabrasion, punch-excision techniques, deep chemical peels, and ablative laser resurfacing.<sup>1-7</sup>

Ablative resurfacing with the carbon dioxide or erbium laser results in destruction of the epidermis followed by reepithelialization with collagen remodeling. This method is typically associated with significant recovery time and can be accompanied by prolonged post-operative erythema, which can persist for months.<sup>1-3,6,7</sup> In addition, ablative laser resurfacing can result in significant and often permanent pigmentary alterations.<sup>1-3,6,7</sup>

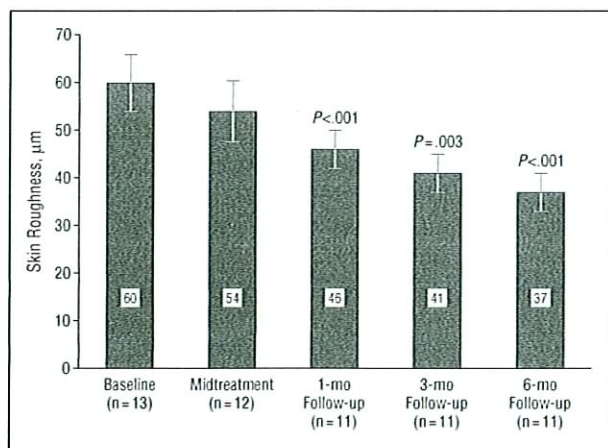
Recently, nonablative lasers, light sources, and radiofrequency devices have been used to selectively deliver thermal energy to the upper dermis, inducing a controlled wound healing response in the papillary and upper reticular dermis without epidermal damage.<sup>8-22</sup> Histologic studies have confirmed production and deposition of new collagen after thermal damage induced by nonablative laser treatments.<sup>10,14,18</sup>

Although previous studies have shown that nonablative laser treatments result in qualitative improvements in facial rhytids and scars, there has been an inherent difficulty in quantifying the effects of nonablative resurfacing.<sup>9-11,14-16,23</sup> Clinical and photographic assessments are subjective and often operator dependent. Thus, a new method was developed using a white-light, noncontacting optical profiler (Phaseshift Rapid In Vivo Mea-





**Figure 1.** Schematic diagram of the Phaseshift Rapid In Vivo Measurement of Skin (PRIMOS) system (GF Messtechnik, Tetlow, Germany). A digital micromirror creates parallel stripe pattern imaging projected onto the skin. Digitized images are obtained via a camera and transferred into a computer where a precise 3-dimensional profile of the skin surface is reconstructed. CCD indicates charge-coupled device.



**Figure 2.** Changes in skin roughness analysis between baseline and 6 months after treatment. Significant improvements were seen as early as 1 month after the fifth treatment with the 1064-nm Q-switched Nd:YAG laser ( $P<.001$ ). Further significant improvements occurred at 3-month ( $P=.003$ ) and 6-month follow-ups ( $P<.001$ ). Bars indicate mean values; limit lines, standard deviation.

surement of Skin [PRIMOS]; GF Messtechnik, Tetlow, Germany) that projects a striped pattern onto the skin surface. Minute differences in surface elevation result in deflection of the parallel stripes from their reference position, which is recorded by a high-resolution digital camera (**Figure 1**) and is used to calculate a point cloud based on x, y, and z coordinates. The image is acquired in less than 100 milliseconds, minimizing noise disturbance caused by normal skin movement. Using a triangulation technique combined with an interferometric technique, the optical profiling imaging system can capture more than 1 million data points in less than 100 milliseconds, delivering a height resolution of approximately 2 µm. The point cloud is visualized with specially written software (IDL; Research Systems Inc, Boulder, Colo) that generates an accurate 3-dimensional model of the skin surface. These surfaces are suitable for quantitating topographic changes such as in the extent of acne scarring or rhytids.<sup>21</sup>

In this study, we used multiple treatment sessions with the 1064-nm Q-switched Nd:YAG laser for the treatment

of atrophic acne scars and quantified the effect by using the optical profiling imaging system and data analysis.

## METHODS

Eleven patients (8 women, 3 men; ages, 28-50 years; skin phototypes, I-III) with mild to moderate atrophic acne scarring were included in the study after informed consent was obtained. A total of 13 sites were treated. Patients with a history of isotretinoin use, filler substance injection, or dermabrasion within the previous year were excluded from the study, as were patients with facial tattoos or permanent makeup.

Each patient received laser treatment of the entire face by a single operator (P.M.F.). A 1064-nm Q-switched Nd:YAG laser (Medlite IV; Continuum, Santa Clara, Calif) was used with an average fluence of 3.4 J/cm<sup>2</sup>, a 6-mm spot size, a 4- to 6-nanosecond pulse duration, and a repetition rate of 10 Hz. Overlapping pulses were delivered until the immediate treatment end point of mild to moderate erythema was achieved. A total of 5 treatments at 3-week intervals were administered.

Objective evaluation of the severity of acne scarring was performed in vivo with the optical profiling imaging system at baseline, after 3 treatment sessions, and at 1, 3, and 6 months after the fifth treatment session. Subjects were positioned in a head restraint for the baseline image. To ensure reproducibility between the images, the baseline image was recalled at half-intensity. The subject's head position was adjusted until it was directly aligned with the baseline image before image capture. Point cloud data were uploaded into the software (RAPIDFORM; INUS Technology Inc, Seoul, Korea), permitting follow-up images to be accurately aligned with the baseline images. The images were registered and trimmed and the difference from a reference plane was calculated as the arithmetic average of the absolute values of all points in the profile (roughness analysis [Ra]). Skin Ra was quantified by means of standard International Organization of Standardization algorithms embedded in the optical profiling analysis software.

The investigator's evaluation of erythema and pinpoint petechiae and the patients' subjective evaluation of pain were graded on an arbitrary 3-point scale: 1, mild; 2, moderate; and 3, severe. If necessary, a topical anesthetic (EMLA cream; Astra USA, Westborough, Mass) was applied 1 hour before laser treatment. Statistical analysis was performed with the paired, 2-tailed *t* test.

## RESULTS

Results were obtained from a total of 13 treatment sites in 11 patients at baseline. Follow-up data were completed for 12 sites after 3 treatment sessions, and for 11 sites at 1, 3, and 6 months after the fifth treatment session. A slight but not significant reduction in Ra was noted at midtreatment, which corresponded to 1 month after the third treatment (from baseline of 60 to 54 µm). Significant reduction in Ra from baseline was seen as early as 1 month after the fifth laser treatment session (from 60 to 46 µm;  $P<.001$ ) (**Figure 2**). Further significant reductions in Ra occurred between the 1-month and 3-month follow-up ( $P=.003$ ), and the 1-month and 6-month evaluations after the fifth treatment session ( $P<.001$ ) (**Figure 2**). Although additional reductions in Ra occurred between the 3- and 6-month follow-up, this difference was not statistically different. Overall, there were significant improvements in Ra score both from baseline and from the 1-month



follow-up to the final 6-month follow-up evaluation after the fifth treatment session (Figure 2).

The 8.9% improvement in Ra was not significant at midtreatment. However, significant improvements of 23.3% in skin roughness were observed 1 month after the fifth treatment ( $P \leq .01$ ), which increased to 31.6% at 3 months ( $P \leq .01$ ) and to 39.2% at 6 months ( $P \leq .01$ ) (Figure 3). Figure 4 demonstrates a clear improvement in the surface topography seen at baseline compared with that seen at 6 months after the last treatment visit. Figure 5 shows the corresponding clinical image at baseline and 6 months after the last treatment visit. Images were from the left cheek of a male patient, adjacent to the nasolabial fold. Pretreatment and posttreatment images were registered before deviation analysis; therefore, measurements accurately assess changes in the anatomic field. The total change measured in this patient was an improvement of 26%.

Overall, patients had only mild to moderate pain, with an average rating of 1.5 on a 3-point scale. Only 2 patients required topical anesthesia before treatment. The only adverse effects noted were transient, mild to moderate erythema (average, 1.9 on a 3-point scale) and mild pinpoint petechiae (average, 1.1 on a 3-point scale). No dyspigmentation or scarring was seen in any patient.

#### COMMENT

Nonablative lasers such as the 585-nm pulsed dye, 1064-nm Q-switched Nd:YAG, 1320-nm Nd:YAG, 1450-nm diode, and 1540-nm erbium:glass lasers, as well as intense pulsed light sources and radiofrequency devices, have been shown to provide qualitative improvements in facial rhytids and scars.<sup>8-25</sup> Most of these systems combine epidermal surface cooling with long wavelengths that allow for penetration into the dermis, resulting in selective dermal thermal injury with preservation of the overlying epidermis. Although all of these systems provide qualitative improvements in rhytids or acne scarring, quantitative improvements have been difficult to demonstrate.

In this study, after 5 treatments with the 1064-nm, Q-switched Nd:YAG laser, significant qualitative and quantitative improvements in facial acne scars were demonstrated. Although a trend toward improvements in acne scarring was noted at midtreatment, these changes were not statistically significant. Significant improvement was seen as early as 1 month after the fifth treatment session, with the greatest percentage of improvements noted at 3 months after the last treatment. Thereafter, improvements were noted to plateau by the 6-month evaluation. The continued improvements we and others have observed several months after the last nonablative laser treatment session suggest that continued long-term dermal remodeling occurs even after cessation of actual laser treatment.<sup>17,24,25</sup> Histologically, mild dermal fibrosis and decrease in solar elastosis with thickening of the papillary dermal collagen have been noted after treatment with the 1064-nm Q-switched Nd:YAG laser.<sup>10,14</sup> These changes are similar to but of a lesser degree than the dermal wound healing response that occurs after ablative laser treatment with the carbon dioxide laser.<sup>3,5</sup> Since new colla-

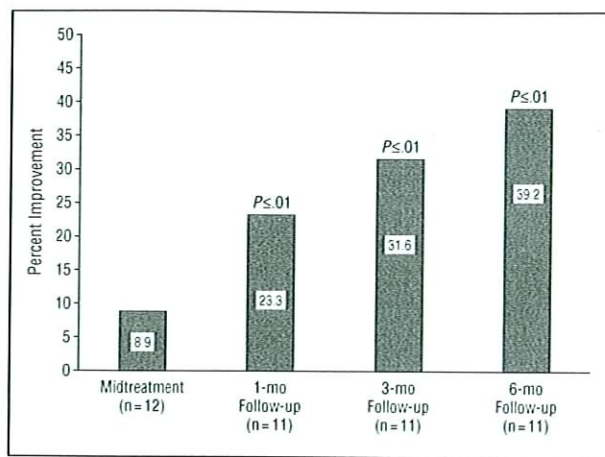


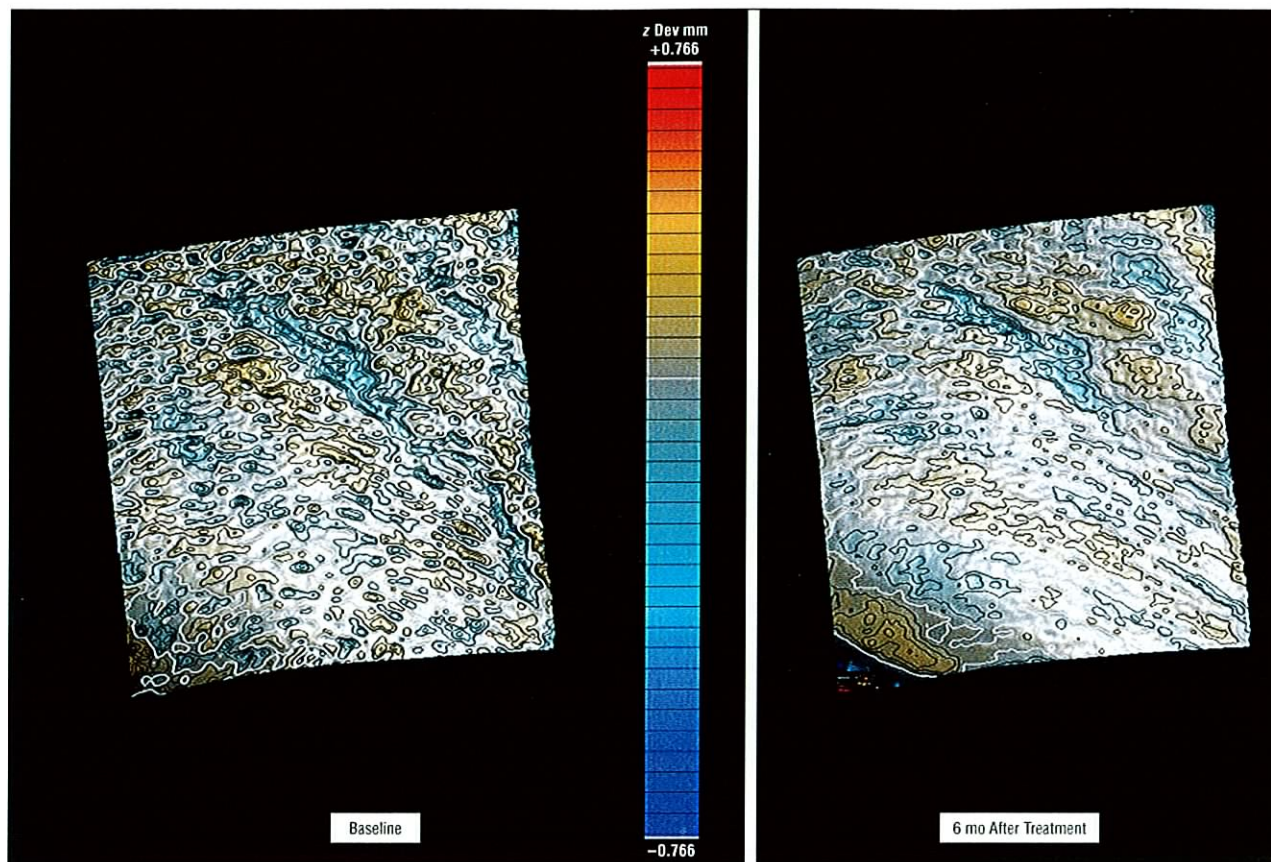
Figure 3. Mean percentage improvement in skin roughness analysis in acne scarring after nonablative laser remodeling.

gen synthesis occurs, the results are expected to be long-lasting, compared with short-term improvements that are seen with filler substances.

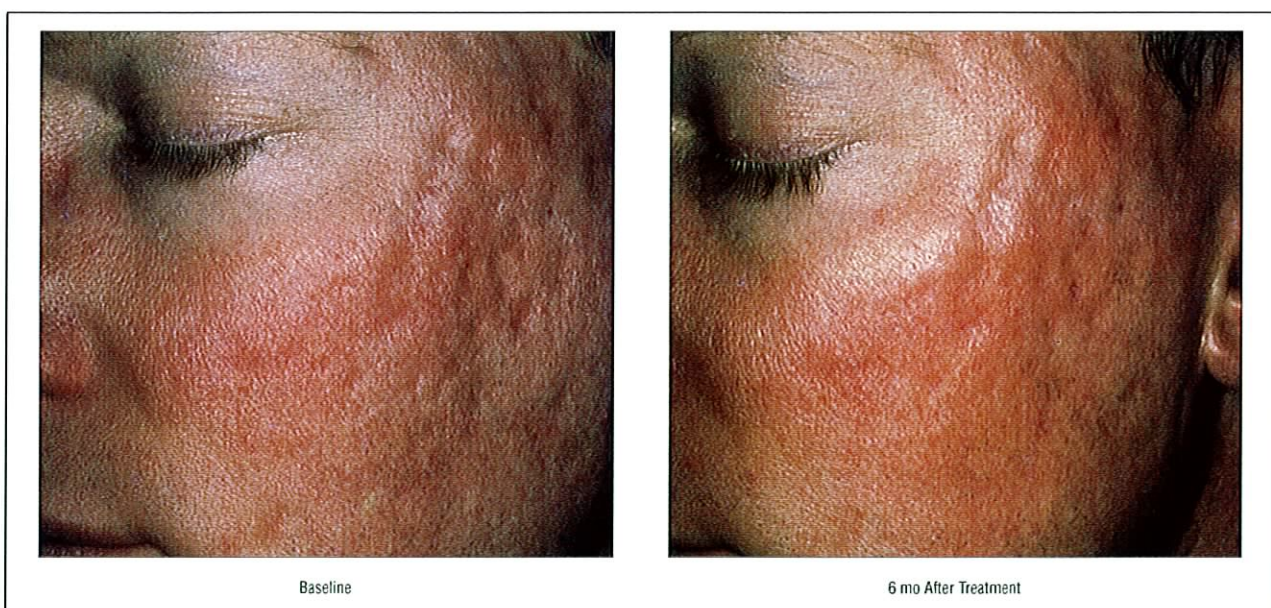This study is also the first, to our knowledge, to quantitatively measure changes in acne scars after nonablative laser treatment with the 1064-nm Q-switched Nd:YAG laser. Previously, quantifying acne scarring and changes in acne scars after laser treatment had been particularly difficult. Initial methods for determining improvement in acne scarring used optical profilometry with the use of silicone rubber replicas to capture skin topography.<sup>23</sup> The measurements obtained by this technique were highly variable and operator dependent. However, in this study, we used the 3-dimensional optical profiling skin measurement device to obtain rapid and in vivo quantitative assessment of improvements in acne scarring. This method provides real-time, objective analysis of the skin surface with minimal noise interference. Nevertheless, minimal positional changes can influence the angle of the light projected onto the surface, potentially leading to variability in baseline and follow-up images. The system enables the user to call up the original image at half intensity and fit the present surface to the original image, ensuring accurate alignment. Furthermore, the ability to digitally register the baseline and follow-up images enables accurate quantification of the change occurring in a precise anatomic location, providing reproducible measurements of changes in surface topography that correlate with clinical changes.<sup>21,24</sup> Because of the length of the trial, other factors may have contributed to the changes observed, such as weight gain or changes in tissue perfusion. These conditions are frequently overlooked in trial design but should be considered in the future because of the improvement in the method to quantify structural surface changes.

In conclusion, this study demonstrated that the 1064-nm Nd:YAG laser provides a safe and effective non-invasive treatment for mild to moderate facial acne scarring. The results are long lasting and continue well beyond the last treatment, indicating ongoing collagen remodeling after completion of the laser treatment sessions. Nonablative treatment with the 1064-nm Q-switched Nd:YAG laser offers significant advantages to patients in terms of its minimal recovery period and mini-





**Figure 4.** High-resolution 3-dimensional images obtained with the optical profiling imaging system illustrating improvements in skin surface topography corresponding to improvement in skin roughness from baseline to the 6-month follow-up. Color-surface topographic images correspond to variations in height in the z plane. The gray color is the zero value while colors going to blue and red represent negative and positive deviations, respectively. The total change or improvement measured in this patient from baseline to the 6-month follow-up was 26%.



**Figure 5.** Clinical image from a male patient showing the left cheek adjacent to the nasolabial fold at baseline and 6 months after the fifth treatment session. The total change measured in this patient was 26%.

mal risk of infectious and pigmentary complications. In addition to documenting the therapeutic effectiveness of nonablative laser treatment in this patient population, we

have developed a method that will enable future studies to accurately measure subtle changes occurring in precise 3-dimensional, anatomic locations.



Accepted for Publication: June 25, 2004.

Correspondence: Paul M. Friedman, MD, DermSurgery Associates, 7515 Main, Suite 240, Houston, TX 77030 (pmfriedman@dermsurgery.org).

Acknowledgment: We express sincere appreciation to Marisol Edward, RN, Judy Dulberg, RN, Alexis Moreno, and Michelle Turnbull, RN, of the Research Department, Laser and Skin Surgery Center of New York, for their clinical assistance; and to Dick Jackson, D-Jackson Software Consulting, Calgary, Alberta, for his invaluable expertise in developing the software for the 3-dimensional image processing and analysis.

## REFERENCES

1. Fitzpatrick R, Goldman M, Satur N, Tope W. Pulsed carbon dioxide laser resurfacing of photoaged skin. *Arch Dermatol*. 1996;132:395-402.
2. Waldorf HA, Kauvar ANB, Geronemus RG. Skin resurfacing of the fine to deep rhytides using char-free carbon dioxide laser in 47 patients. *Dermatol Surg*. 1995;21:940-946.
3. Alster TS, Nanni CA, Williams CM. Comparison of four carbon dioxide resurfacing lasers: a clinical and histopathologic evaluation. *Dermatol Surg*. 1999;25:153-159.
4. Nelson B, Majmudar G, Griffiths CE, et al. Clinical improvement following dermabrasion of photoaged skin correlates with synthesis of collagen I. *Arch Dermatol*. 1994;130:1136-1140.
5. Cotton J, Hood AF, Gonin R, Beesen WH, Hanke CW. Histologic evaluation of preauricular and postauricular human skin after high energy, short-pulse carbon dioxide laser. *Arch Dermatol*. 1996;132:425-428.
6. Tanzi EL, Alster TS. Treatment of atrophic facial acne scars with a dual-mode Er:YAG laser. *Dermatol Surg*. 2002;28:551-555.
7. Jeong JT, Kyr YC. Resurfacing of pitted facial acne scar with a long-pulsed Er:YAG laser. *Dermatol Surg*. 2001;27:107-110.
8. Zelickson BD, Kilmer SL, Bernstein E, et al. Pulsed dye laser for sun damaged skin. *Lasers Surg Med*. 1999;25:229-236.
9. Goldberg DJ, Whitworth J. Laser skin resurfacing with the Q-switched Nd:YAG laser. *Dermatol Surg*. 1997;23:903-907.
10. Cisneros JL, Rio R, Palou J. The Q-switched neodymium (Nd):YAG laser with quadruple frequency: clinical histological evaluation of facial resurfacing using different wavelengths. *Dermatol Surg*. 1998;24:345-350.
11. Goldberg DJ, Silapunt S. Q-switched Nd:YAG laser: rhytid improvement by nonablative dermal remodeling. *J Cutan Laser Ther*. 2000;2:157-160.
12. Khatri KA, Ross EV, Grevelink JM, Magro CM, Anderson RR. Comparison of erbium:YAG and carbon dioxide lasers in resurfacing of facial rhytides. *Arch Dermatol*. 1999;135:391-397.
13. Alster TS. Clinical and histologic evaluation of six erbium:YAG lasers for cutaneous resurfacing. *Lasers Surg Med*. 1999;24:87-92.
14. Goldberg DJ, Silapunt S. Histologic evaluation of a Q-switched Nd:YAG laser in the nonablative treatment of wrinkles. *Dermatol Surg*. 2001;27:744-746.
15. Menaker GM, Wrone DA, Williams RM. Treatment of facial rhytides with a nonablative laser: a clinical and histologic study. *Dermatol Surg*. 1999;25:440-444.
16. Levy JL, Trelles M, Lagarde JM, Borrel MT, Mordon S. Treatment of wrinkles with the nonablative 1320 nm Nd:YAG laser. *Ann Plast Surg*. 2001;47:482-488.
17. Tanzi EL, Alster TS. Comparison of a 1450 nm diode laser and a 1320 nm Nd:YAG laser in the treatment of atrophic facial scars: a prospective clinical and histologic study. *Dermatol Surg*. 2004;30:152-157.
18. Fournier N, Dahan S, Barneon G, et al. Nonablative remodeling: clinical, histologic, ultrasound imaging, and profilometric evaluation of a 1540 nm Er:glass laser. *Dermatol Surg*. 2001;27:799-806.
19. Goldberg DJ, Samady J. Intense pulsed light and Nd:YAG laser non-ablative treatment of facial rhytides. *Lasers Surg Med*. 2001;28:141-144.
20. Goldberg DJ, Cutler KB. Nonablative treatment of rhytides with intense pulsed light. *Lasers Surg Med*. 2000;26:196-200.
21. Friedman PM, Skover GR, Payonk G, Kauvar ANB, Geronemus RG. 3D in-vivo optical skin imaging for topographical quantitative assessment of non-ablative laser technology. *Dermatol Surg*. 2002;28:199-204.
22. Ruiz-Esparza J, Barba Gomez J. Nonablative radiofrequency for active acne vulgaris: the use of deep dermal heat in the treatment of moderate to severe active acne vulgaris (thermotherapy): a report of 22 patients. *Dermatol Surg*. 2003;29:333-339.
23. Rogachefsky AS, Hussain M, Goldberg DJ. Atrophic and a mixed pattern of acne scars improved with a 1320-nm Nd:YAG laser. *Dermatol Surg*. 2003;29:904-908.
24. Friedman PM, Skover GR, Payonk G, Geronemus RG. Quantitative evaluation of nonablative laser technology. *Semin Cutan Med Surg*. 2002;21:266-273.
25. Fournier N, Dahan S, Barneon G, et al. Nonablative remodeling: a 14 month clinical, ultrasound imaging and profilometric evaluation of a 1540 nm Er:glass laser. *Dermatol Surg*. 2002;28:926-931.

## News and Notes

**Dates of 2005 ABD Examinations:** In 2005, the certifying examination of the American Board of Dermatology (ABD) will be held at the Holiday Inn O'Hare International in Rosemont, Ill, on August 14 and 15, 2005. The deadline for receipt of applications is March 1, 2005.

The recertification examination of the ABD will be administered online from May 2 to June 16, 2005. The deadline for receipt of applications for the recertification examination is January 1, 2005.

The examination for subspecialty certification in dermatopathology will be administered September 15 and 16, 2005, at the testing center of the American Board of Pathology in Tampa, Fla. The deadline for receipt of applications is May 1, 2005. Dermatologists must submit applications to the American Board of Dermatology and pathologists to the American Board of Pathology.

The next examination for subspecialty certification in pediatric dermatology will be administered in 2006 (the date will be announced in 2005).

The in-training examination for dermatology residents (administered online at dermatology residency training centers in the United States and Canada) will be held on April 21, 2005. The deadline for receipt of applications is February 1, 2005.

For further information about these examinations, please contact Antoinette F. Hood, MD, Executive Director, American Board of Dermatology, Henry Ford Health System, 1 Ford Place, Detroit, MI 48202-3450 (phone: 313-874-1088; fax: 313-872-3221; e-mail: abderm@hfhs.org; Web site: www.abderm.org).